



Published for the
dental professional
community by the
American
Association of
Endodontists.

Fall/Winter
1996

ENDODONTICS

COLLEAGUES FOR EXCELLENCE

When Patients Run Hot and Cold: Guidelines for Endodontic Diagnosis

Endodontic diagnosis often presents challenges for the practitioner. Consider the following scenarios:

- A patient named Barbara comes into your office and tells you the following story: "I've been experiencing pain every time I put something cold in my mouth. It seems to be getting worse. Last night, I tried to drink iced tea, and the pain was really severe."
- Another patient, Joe, enters the office carrying a cup of ice water and reports the opposite problem: "I have a terrible toothache. For the last few days, it hurt whenever I ate or drank something hot. Last night, I tried to eat hot soup, and the pain was worse than it has ever been. That's why I'm carrying this cup of ice water. If I sip ice water every few minutes, I get relief. But as soon as I stop drinking the ice water, the toothache comes right back."

- A patient named John reports having had an intermittent, spontaneous toothache for several weeks. "Now, it hurts when I chew, and I think it's getting worse."

Barbara, Joe, and John present endodontic diagnostic challenges, and they want immediate relief. The task at hand is to determine the involved tooth and cause of the pain and then to render appropriate treatment.

This issue of *ENDODONTICS: Colleagues for Excellence* emphasizes a systematic approach to endodontic diagnosis. The information presented here will provide insight into how to reach a diagnosis when the patient's chief complaint is pain to a thermal stimulus or chewing pressure and how controlled exposure to a thermal stimulus in the dental office can help the practitioner isolate the source of orofacial pain. ■

Guidelines for Endodontic Diagnosis

Most orofacial pain is of pulpal or periradicular origin, and pain to thermal stimulus is often an indication of an endodontic problem. The following system is recommended for diagnosis and treatment planning:

Ascertain the Chief Complaint. Significant pulpal and periradicular pathosis is often asymptomatic, but, when the patient does report a specific complaint, you have your first clue in discovering the location and etiology of the problem.

Take a Detailed Medical and Dental History. The periodontium, jaws, sinuses, ears, temporomandibular joints, masticatory musculature, nose, eyes, blood vessels, and other structures may induce pain that mimics pulpal pain. Other pathologic conditions—such as neuralgia, multiple sclerosis, myocardial ischemia, and psychiatric disorders—may also produce symptoms that are confused with tooth pain. To avoid misdiagnosis and to rule out orofacial pain that is not of endodontic origin, the clinician should identify and document all signs and symptoms.

Conduct All Necessary Objective and Subjective Examinations. These include observation, pulp testing, and radiographic examinations. The clinician should also elicit from the patient the history of the present illness and ask the patient to identify the involved tooth, if the patient is able to do so.

Analyze the Data. While one piece of the puzzle may not lead to a correct diagnosis, an analysis of all the data considered as a whole will usually present a clearer picture of the problem.

Formulate an Appropriate Diagnosis and Treatment Plan. It is obviously critical to treat the correct tooth and to decide whether endodontic treatment needs to be performed immediately or can be scheduled at a later date without adverse consequences to the patient.

The following case studies demonstrate how applying this system helps the dentist reach the correct diagnosis.

Case #1

Barbara Complains of Pain to Cold

Barbara, the woman who experienced severe pain when sipping iced tea, was examined by Dr. A. Her medical history showed no contributing factors. Current signs and symptoms also showed no contributing factors. Upon examination, Dr. A found no caries, tooth fractures, or other pathosis. The patient seemed to have a dentition in good repair.

Barbara's complaint of pain to thermal stimulation led Dr. A to suspect an inflamed or degenerating vital pulp. Her dental history and the radiographic examination revealed several long-standing, moderately deep restorations in her posterior teeth (Fig. 1).

Although radiographs are a valuable tool in endodontic diagnosis, the clinician should keep in mind the following diagnostic **limitations** of radiographs:

- When the pulp is vital, a radiograph is unlikely to show the cause of the pain.
- While radiographs may give a hint—such as large restorations or caries not evident in the clinical exam—there will probably be no “smoking gun” (periradicular lesion) on the film.

- As a general rule, then, radiographs are unlikely to pinpoint the etiology of pain elicited by temperature extremes.

Recognizing the limitations of radiographs, Dr. A chose pulp tests based on Barbara's chief complaint—pain to cold. He reasoned that a cold test would determine the offending tooth. He also chose a percussion test to indicate or rule out acute apical periodontitis, which is often associated with irreversible pulpitis. He used an ice stick to perform the cold test and tested healthy control teeth first.

In testing for pain to cold, Dr. A has found that patients can suspect the wrong tooth. Using controls helped Barbara learn what to expect from the stimulus and gave Dr. A an idea of the nature of her normal response, because many patients feel moderate pain to cold in all teeth. Dr. A's goal in cold testing was to find the tooth that was different and to reproduce the complaint.

In Barbara's case, Dr. A found severe, lingering pain to cold from tooth #30, which was consistent with her complaint, with no other significant findings. Dr. A did not use an electric pulp tester, because a response to cold had already

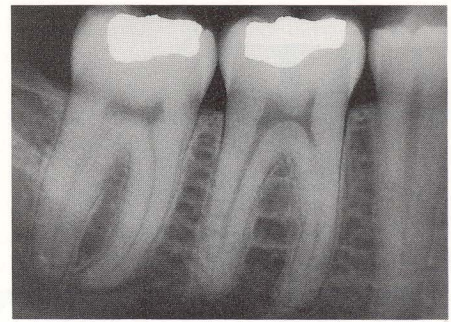


Figure 1

established pulp vitality. The patient had no pain to pressure, no recent dental work, no gingival recession, and no caries. Dr. A diagnosed irreversible pulpitis of tooth #30. He recommended root canal treatment and a full-cuspal coverage restoration. Antibiotic therapy was not indicated, because the pulp was vital.

If Dr. A had relied solely on the radiograph and elected to watch rather than treat the problem, then Barbara might have experienced the preliminary symptoms of irreversible pulpitis over many months. Barbara probably would have learned to deal with this by protecting the tooth from temperature extremes. Over time, however, as the inflammation spread and ultimately led to infection, the symptoms would have progressed to include pressure sensitivity, spontaneous pain, and finally continuous pain.

Dr. A followed a system, came to the correct diagnosis, and saved this patient from unnecessary suffering and inconvenience. ■

Case #2

Joe Complains of Pain to Heat

Joe, the patient who walked into the dental office carrying a cup of ice water and complaining of pain to heat, was examined by Dr. B.

When asked to locate the source of the pain, Joe was unsure. He knew it was on the left side of his mouth, but he could not be certain whether it was from an upper or lower tooth. Joe had noticed no other signs or symptoms at this point, saying that he had experi-

enced this severe toothache over the last few days whenever he ate or drank something hot.

A review of the patient's record showed that two teeth—#18 and #19—had deep restorations placed during the past two years. Generalized pulp calcification was evident on previous radiographs. Upon further questioning, the patient remembered having had pain to cold temperatures for months after the restorations were placed. “I didn't bother to come back right away,” Joe said, “and it must have gotten better with time, or I just got used to it.”

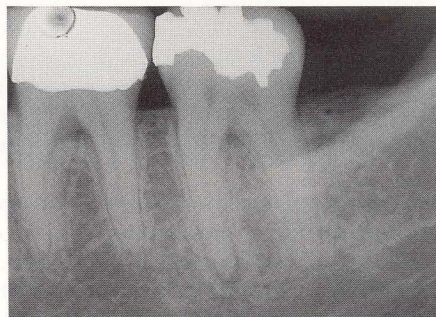


Figure 2

A new radiograph (Fig. 2) showed thickening of the PDL of the mesial root of tooth #18. However, both #18

continued on next page

**Case #2
continued**

and #19 were sensitive to percussion. Dr. B explained to Joe that she needed to use a thermal test to determine for certain which tooth was the culprit. "Because higher temperatures are making your tooth hurt, I could apply heat to one tooth at a time to reproduce the pain. When the pain starts again, we will know which tooth is the culprit. However, I think the test will be more comfortable for you if I perform it in reverse. If you stop sipping the ice water for a while and let me know when the pain returns, I can cool one tooth at time with an ice stick until the pain stops."

Joe immediately understood why this was necessary. "I don't want you working on the wrong tooth," he said and stopped sipping the ice water. In a short time the pain returned. Dr. B

began by cooling #19 with the ice stick. When this gave no relief, she placed ice on #18, and in just a few seconds the pain began to diminish. This confirmed her suspicion of irreversible pulpitis and acute apical periodontitis of tooth #18. Because lower molars are particularly difficult to anesthetize and generalized pulp calcification was evident on the radiograph Dr. B elected to refer Joe to an endodontist for root canal treatment.

If Dr. B had not performed thermal testing, she would have been unable to locate the source of the pain, and the pathosis would likely have progressed within a few days to a necrotic pulp. However, by following systematic diagnostic procedures, Dr. B was able to achieve an accurate diagnosis, and take action to ensure immediate relief. ■

Case #3

John Complains of Intermittent Spontaneous Pain

John, the patient reporting an intermittent spontaneous toothache, was examined by Dr. C. Several days before his appointment, John noticed increasing pain when chewing in the area of teeth #5 and #6.

John's medical history showed no contributing factors, and he reported no other signs or symptoms. Tooth #5 was the mesial abutment for a three-unit bridge. Tooth #6 had a small distal amalgam restoration. Dr. C found #5 and #6 were equally painful to percussion. On palpation, she noted tenderness and a slight periradicular swelling in the region of #5 and #6.

Dr. C suspected that the pathosis would be located in tooth #5,

because that tooth had a full coverage restoration, while tooth #6 had only a small amalgam restoration. A radiograph seemed to confirm her suspicion, showing a periradicular lesion associated with

tooth #5 (Fig. 3). Recognizing the limitations of radiographs, however, she used a cold test to confirm her diagnosis.

In testing tooth #5, Dr. C first tried to apply ice to the metal collar or exposed tooth structure, but this was not possible. She then applied ice near the gingival margin, testing a control tooth first so that John could differentiate between a response coming from the gingiva and a response coming from the tooth. Tooth #5 had a mild, normal response to ice, while #6 was unresponsive. Perplexed, she performed an electric pulp test on #6.

(She did not perform an electric pulp test on #5, because it is not possible to do an effective electric pulp test on a tooth with a crown, and the response to cold had already indicated pulp vitality.) Again, tooth #6 was unresponsive. Based on these results, Dr.

C began to suspect that the pathosis was located not in tooth #5, as she had originally suspected, but in tooth #6. She took a second radiograph from a different angle, which confirmed that the pathosis

was actually centered around tooth #6 (Fig. 4). She diagnosed pulpal necrosis with acute periradicular abscess of #6 and recommended endodontic treatment and appropriate restoration.

This case demonstrates the importance of using not only radiographs but also

confirmatory pulp tests to reach a correct diagnosis. Dr. C's diligence in following a proper endodontic diagnostic protocol—including pulp testing—led to a correct diagnosis and an acceptable outcome. ■

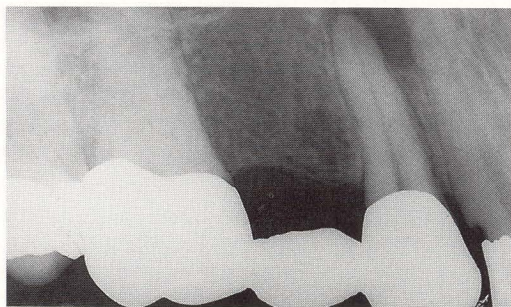


Figure 3

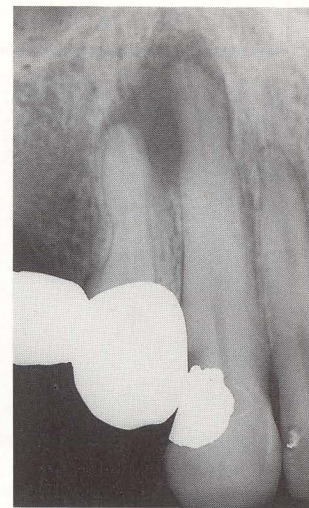
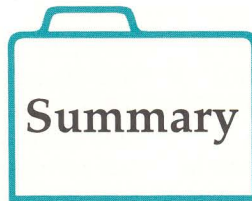

Figure 4

The goal in pulp testing is to find the tooth that is different and to reproduce the complaint.

The three case studies presented demonstrate a few common diagnostic dilemmas encountered daily in dental offices. Each case presents a patient with different complaints and symptoms. What each case shares is the need for the dentist to use his/her knowledge and critical thinking skills to gather and sort through all available information to determine the correct diagnosis. This newsletter includes a summary outline of the endodontic diagnosis system as an insert.



Each evaluation begins with an interview of the patient to ascertain the chief complaint. An updated medical and dental history is reviewed, as well as all current signs and symptoms.

Next, clinical information must be collected through subjective, objective, and radiographic examinations. Pulp testing is intended to reproduce the patient's chief complaint in the controlled environment of the dental operator. Tests should recreate, individually for each tooth, the stimulus that elicits pain.

The clinician must keep in mind that thermal pain is caused by vital pulp tissue and use appropriate tests to determine the source. Swelling or drainage of infection are byproducts of pulpal necrosis. Pain to pressure and spontaneous toothache can be the result of either vital or nonvital pulp pathosis. Critical thinking is necessary to determine what information should be gathered in the investigative phase of diagnosis.

Once the appropriate data have been collected and analyzed, the preliminary diagnosis should be reviewed to be certain it fits with all the signs and symptoms. Confirmatory tests help prevent misdiagnosis and inappropriate treatment. Not all orofacial pain is of endodontic origin. If the data gathered do not support your conclusion, consider referral to an appropriate

dental or medical specialist. Endodontists can be a valuable resource because of their special training and experience in diagnosing and treating difficult and unusual cases.

Regardless of technical excellence, a root canal procedure performed on the wrong tooth is always a failure!

While there is no guarantee of success in every case, the American Association of Endodontists hopes this issue of *ENDODONTICS: Colleagues for Excellence* will aid in achieving accurate diagnosis of endodontic pathosis. Practitioners must always use their best professional judgment in individual situations. The AAE neither expressly nor implicitly warrants any positive results nor expressly nor implicitly warrants against any negative results associated with the application of this information.

If you would like more information on endodontic diagnostic considerations, call your local endodontist or write to the American Association of Endodontists, 211 E. Chicago Ave., Ste. 1100, Chicago, IL 60611-2691, 312/266-7255, fax 312/266-9867. References are available upon request. ■

On the Horizon

Enhanced vision helping endodontists see inside the root canal system

Root canal treatment has been described as the art of treating the smallest of tissues in the most difficult of locations. Patients are often amazed when they have the opportunity to see the tiny, remote spaces in which general dentists and endodontists routinely work.

Endodontists have long been leaders in the use of enhanced illumination and magnification for dentistry. Surgical binoculars, operating headlamps, and fiber optic illumination have been a part of the endodontist's armamentarium for many years.

The surgical operating microscope is on the horizon as an addition to this armamentarium. The first surgical microscopes were introduced in this country in the early 1940s by

otolaryngologists, who appreciated the illumination and magnification they could achieve with the microscope.

Endodontists initially used today's modern microscopes for surgery. Many have found that further magnification and illumination of the surgical field can be beneficial to the practitioner.

In addition, the microscope can aid in diagnosis and nonsurgical root canal treatment. The microscope can also assist in locating unusually positioned canal orifices and may be used for added magnification and illumination during retreatments and other challenging procedures.

With the microscope, structures that are barely detectable with the naked eye become easier to see. For

example, an isthmus frequently runs between two canals in the mesiobuccal root of the maxillary first molar. These small isthmuses should be included in root-end preparations and root-end fillings. They are more easily located with magnification, allowing them to be prepared with the main canals.

The microscope is also a useful education tool. With built-in video, students and practitioners can observe live procedures. Treatments may also be videotaped for later viewing.

By exploring new methods of illumination and magnification, endodontists continue to advance the leading edge of technology, making those tiny canals seem a little larger and more accessible. ■

Comments?

Did you enjoy this issue of *ENDODONTICS*? Did the information have a positive impact on your practice? Are there topics you would like *ENDODONTICS* to cover in the future? We want to hear from you! Send your comments, questions, and suggestions to:

ENDODONTICS

American Association of Endodontists
211 East Chicago Avenue, Suite 1100
Chicago, IL 60611-2691



Fall/Winter 1996 ENDODONTICS: Colleagues for Excellence
When Patients Run Hot and Cold: Guidelines for Endodontic Diagnosis
Selected References

Classification/Assessment

Gutmann JL, Dumsha TC, Lovdahl PE, and Hovland EC. *Problem Solving In Endodontics*. Chapter 9, Mosby-Year Book, Inc., St. Louis, 1997.

Peters DD, Baumgartner JC, Lorton L. Adult pulpal diagnosis. I. Evaluation of the positive and negative responses to cold and electrical pulp tests. *Journal of Endodontics* 20:506-511, 1994.

Himel VT. Diagnostic procedures for evaluating pulpally involved teeth. [Review]. *Current Opinion in Dentistry* 2:72-77, 1992.

Klausen B, Helbo M, Dabelsteen E. A different diagnostic approach to the symptomatology of acute dental pain. *Oral Surgery, Oral Medicine, Oral Pathology, Oral Radiology, & Endodontics* 59:297-301, 1985.

Morse DR, Seltzer S, Sinai I, and Biron G. Endodontic classification. *Journal of the American Dental Association* 94(4):685-689, 1977.

Cecic PA, Hartwell GR, Bellizzi R. Cold as a diagnostic aid in cases of irreversible pulpitis. *Oral Surgery, Oral Medicine, Oral Pathology, Oral Radiology, & Endodontics* 56:647-650, 1983.

Dummer PM, Hicks R, and Huws D. Clinical signs and symptoms in pulp disease. *International Endodontic Journal* 13(1):27-35, 1980.

Facial Pain

Ingle JI and Bakland LK. *Endodontics*. Chapters 10 & 11 Williams & Wilkins, Baltimore, 1994.

Klausner JJ. Epidemiology of chronic facial pain: diagnostic usefulness in patient care. [Review]. *Journal of the American Dental Association* 125(12):1604-1611, 1994.

Pertes RA and Heir GM. Chronic orofacial pain. A practical approach to differential diagnosis. [Review]. *Dental Clinics of North America* 35(1):123-140. 1991.

Bennett GJ and Sessle BJ. Basic science issues related to improved diagnoses for chronic orofacial pain. [Review]. *Anesthesia Progress* 37(2-3):108-112, 1990.

Emergency Treatment

Gutmann JL, Dumsha TC, Lovdahl PE, and Hovland EC. *Problem Solving In Endodontics*. Chapter 9, Mosby-Year Book, Inc., St. Louis, 1997.

Fouad AF, Rivera EM, Walton RE. Penicillin as a supplement in resolving the localized acute apical abscess. *Oral Surgery, Oral Medicine, Oral Pathology, Oral Radiology, & Endodontics* 81(5):590-595, 1996.

Hasselgren G and Calev D. Endodontics emergency treatment sound and simplified. *New York State Dental Journal* 60:31-33, 1994.

Torabinejad M and Walton RE. Managing endodontic emergencies. *Journal of the American Dental Association* 122(6):99, 1991.

Cooper SA. Treating acute pain: do's and don'ts, pros and cons. *Journal of Endodontics* 16:85-91, 1990.

Hasselgren G, Reit C. Emergency pulpotomy: pain relieving effect with and without use of sedative dressings. *Journal of Endodontics* 15:254-256, 1989.

Radiographic Assessment

Gutmann JL, Dumsha TC, Lovdahl PE, and Hovland EC. *Problem Solving In Endodontics*. Chapter 2, Mosby-Year Book, Inc., St. Louis, 1997.

Walton RE. Radiology and endodontics [editorial]. *Oral Surgery, Oral Medicine, Oral Pathology, Oral Radiology, & Endodontics* 80(5):495, 1995

Nattress BR and Martin DM. Predictability of radiographic diagnosis of variations in root canal anatomy in mandibular incisor and premolar teeth. *International Endodontic Journal* 24(2):58-62, 1991.

Molven O, Halse A, and Grung B. Observer strategy and the radiographic classification of healing after endodontic surgery. *International Journal of Oral & Maxillofacial Surgery* 16(4):432-439, 1987.

Walton RE. Endodontic radiographic technics. *Dental Radiography & Photography* 46(3):51-59, 1973.

Operating Microscope

Weller RN, Niemczyk SP, Kim S. Incidence and position of the canal isthmus. Part 1. Mesio Buccal root of maxillary first molar. *Journal of Endodontics* 21:380-383, 1995.

Cohen S and Burns RC. Ed *Pathways of the Pulp*. Chapter 15, 6th Ed., Mosby-Year Book, Inc., St. Louis, 1994.

Pecora G and Andreana S. Use of dental operating microscope in endodontic surgery. *Oral Surgery, Oral Medicine, Oral Pathology* 75(6):751-758, 1993.

Carr G. Advanced techniques and visual enhancement for endodontic surgery. *Endodontic Report* 7(1):6-9, 1992.

Carr GB. Microscopes in endodontics. *Journal of the California Dental Association* 20(11):55-61, 1992.